



USES OF CAPNOGRAPHY (ACTAS):

- verify initial position of ETT
- monitor continuing tracheal position of ETT
- assist in assessment of adequacy of chest compressions
- assist with confirmation of ROSC
- aid in determination of cessation of resuscitation efforts
- monitor effective IPPV in patients with critical CO₂ requirements

MONITORING PROCEDURE:

1. Open CO₂ connector door on monitor, connect Microstream tubing by turning clockwise. (The monitor will sense the presence of the tubing and activate the EtCO₂ function automatically. Self-test, auto-zeroing and warm up may take up to 2 ½ minutes).
2. Connect the tubing to the patient (distal to the bacterial filter is preferred).
3. Display EtCO₂ waveform on channel 3.
4. Adjust scale if required. (Monitor is configured to “Autoscale”. This means that the monitor will over-select the scale based on the measured EtCO₂ measurement).
5. The EtCO₂ is displayed in mmHg. A respiratory rate is also displayed. (No respiratory rate is displayed if the EtCO₂ is less than 8mmHg. The waveform is still valid).

Note: rapid altitude changes may cause the machine to attempt to purge the tubing. If this occurs, disconnect the tubing briefly from the monitor, and then reconnect it.

INTERPRETATION OF RESULTS:

- It is important to utilise waveform to assist in interpretation of information; do not rely only on the numerical reading.
- NOTE: PaCO₂ is generally 3mmHg higher than EtCO₂.
- Critical values in critical patients:
 - **cardiac arrest:** EtCO₂ consistently above 15mmHg seems to have some positive correlation with ROSC
 - patients with **acute intracranial pathology** – PaCO₂ should be in the range of 30 – 45mmHg. Therefore, *EtCO₂ should be in the range of 27 – 40mmHg*

continues over

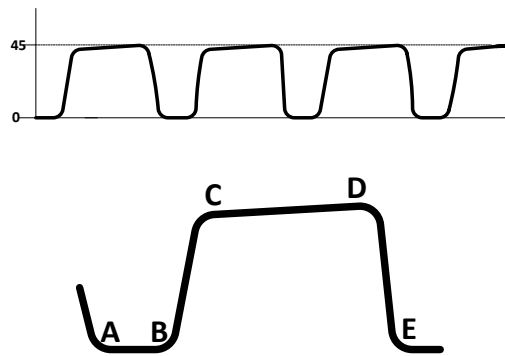


DOCUMENTATION OF RESULTS:

- Serial EtCO₂ readings may be recorded in the appropriate section of the ACTAS PCR.
- Waveform printouts (important for verification of ETT placement) may be attached to the PCR from either a screen print or the code summary.
- EtCO₂ values will be included in the vital signs summary printout for later reference.

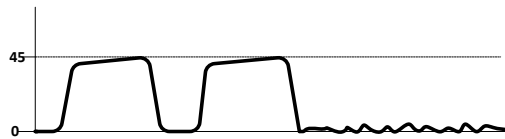
Normal waveform:

- A – B** Respiratory baseline
- B – C** Expiratory upslope
- C – D** Expiratory plateau
- D** End-tidal value – peak CO₂ concentration – at the end of the exhalation
- D – E** Inspiratory downstroke



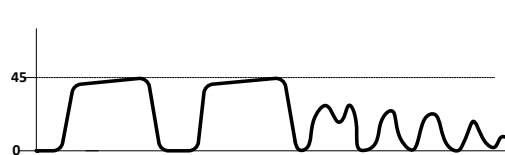
Sudden loss of waveform, EtCO₂ near zero:

- ET tube disconnected, dislodged, kinked or obstructed
- loss of circulatory function



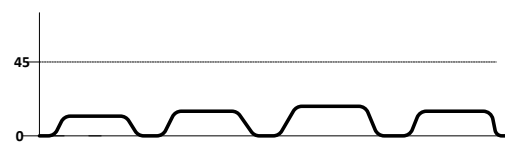
Decreasing EtCO₂ with loss of plateau:

- ETT cuff leak or deflated cuff
- ETT in hypopharynx
- partial obstruction



CPR assessment:

- attempt to maintain minimum 10mmHg



Sudden increase in EtCO₂:

- return of spontaneous circulation

